

# Abdominal Cocoon Syndrome: A Rare Sequelae of Intestinal Perforation

ABHILASHA BHARGAVA<sup>1</sup>, CHANDRASHEKHAR MAHAKALKAR<sup>2</sup>, SHIVANI KSHIRSAGAR<sup>3</sup>, SIMRAN DHOLE<sup>4</sup>

(CC) BY-NC-ND

## ABSTRACT

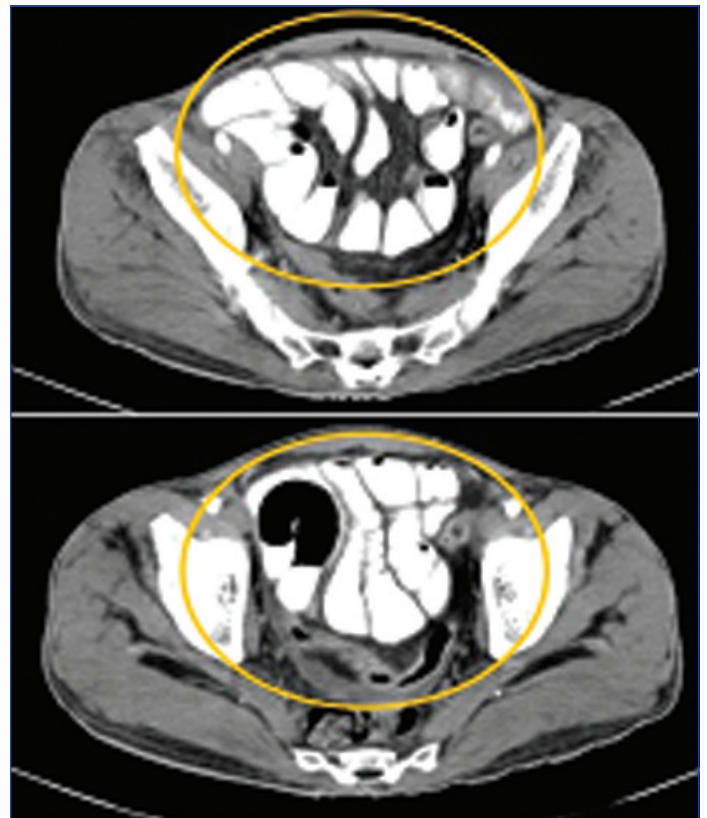
Abdominal cocoon syndrome is a rare clinical presentation that has been associated with abdominal tuberculosis in rural India. It is also known as sclerosing encapsulating peritonitis, where the small bowel becomes encapsulated by a fibrous membrane due to unclear causes, leading to obstipation. Common symptoms include vomiting, nausea, and constipation. Due to these general clinical symptoms, it can be mistaken for other gastrointestinal disorders, resulting in delayed diagnosis, which may lead to adverse outcomes or even mortality. Surgery is often used to free the entrapped bowel and remove the fibrous tissue, while supportive care and problem management are crucial. The present case involves a 55-year-old male who presented with a distended abdomen and obstipation, leading to intestinal perforation and sclerosing encapsulating peritonitis, which was managed through resection and anastomosis of the small intestine. The patient was followed-up after three months with no new complaints. The present case helps in understanding the sequelae of acute intestinal perforation that can result in abdominal cocoon syndrome.

**Keywords:** Acute abdomen, Case report, Constipation, Perforation peritonitis, Sclerosing encapsulating peritonitis

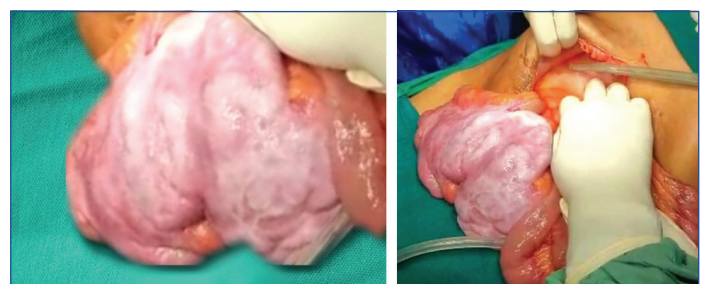## CASE REPORT

A 55-year-old male presented to the emergency ward with a distended abdomen, complaints of obstipation, and vomiting for two days. On examination, the patient had tachycardia and was normotensive. There was no history of similar complaints or any past surgeries. Perabdominal examination showed the abdomen to be tender, rigid with guarding, and distended. On percussion, a dull note was appreciated over the abdomen. On auscultation, the bowel sounds were sluggish. He presented with leucocytosis, hypoalbuminaemia, and marginally high liver enzymes. He was shifted to the Intensive Care Unit (ICU) for close monitoring. The ultrasound of the abdomen could not determine the level of perforation as most of it was obscured by bowel gas. Therefore, a Contrast-enhanced Computed Tomography (CECT) abdomen was performed, which suggested a jejunal perforation along with a mass approximately 9.2×8.4 cm adhered to small bowel loops in a capsulated form resembling a cocoon and gross ascites. Based on the CECT findings, a radiological diagnosis of abdominal cocoon syndrome with intestinal perforation and gross ascites was made [Table/Fig-1]. The patient underwent emergency exploratory laparotomy. Intraoperatively, upon incising the peritoneum, 2.5-3 litres of clear fluid were suctioned out. Evidence of a mass comprising loops of small intestine covered with a thick, translucent, whitish membrane resembling a cocoon was observed [Table/Fig-2,3]. After careful dissection of the membrane and probing the loops of the small intestine, a jejunal perforation of 2×2.5 cm was found, 200 cm distal to the Double J (DJ) flexure [Table/Fig-4]. In the present case, jejuno-jejunal resection and anastomosis were performed to correct the intestinal perforation. After addressing the aetiology of the perforation, the patient was closely monitored until the recovery of normal peristalsis. As the patient passed stools and was asymptomatic postoperatively, no active intervention was required apart from observation and regular follow-up.

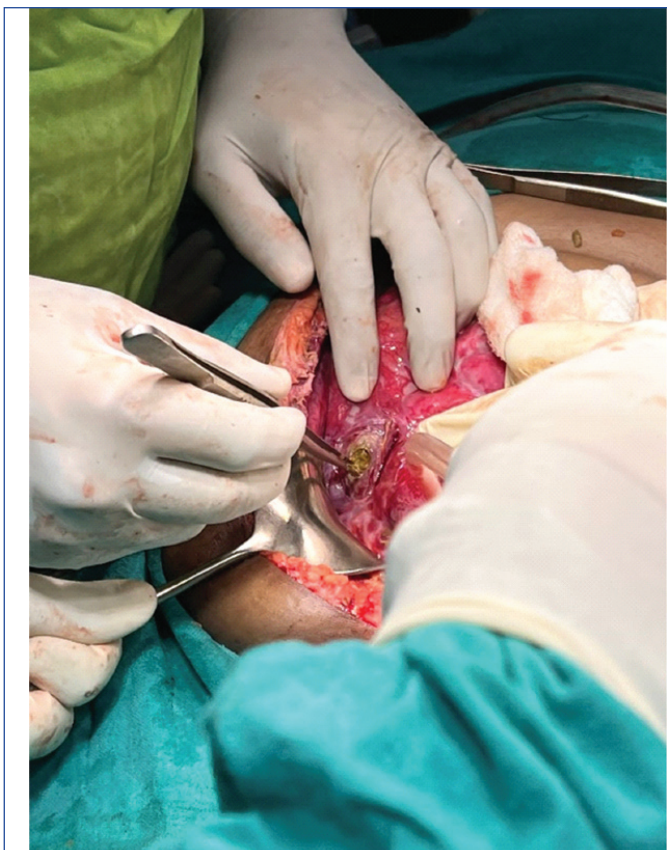The postoperative Intensive Care Unit (ICU) stay of the patient was uneventful. The abdominal drain was removed on postoperative day 5, and suture removal was performed on day 10. During the follow-up after three months, the patient presented with a healthy scar site and no new complaints.



**[Table/Fig-1]:** CECT abdomen: Encircled area showing small bowel arranged like a cocoon in the abdominal cavity.



**[Table/Fig-2]:** Clinical image showing small bowel encapsulated in the form of cocoon. **[Table/Fig-3]:** Intraoperative image showing evacuation of gross ascites. (Images from left to right).



[Table/Fig-4]: Intraoperative image of perforation 200 cm distal to DJ flexure.

'Abdominal cocoon' in 1978 by Foo KT et al., [1]. The disorder is called 'cocoon syndrome' due to an abnormal membrane surrounding some portion or all of the small intestine. Common clinical presentations of this disease include abdominal pain, nausea, vomiting, abdominal mass, or distension [2]. An unclear inflammatory process has been listed as an underlying cause of this acquired disorder. Males are more likely to have abdominal cocoon syndrome compared to females with a ratio of 1.2-2:1 [3] and has been classified into primary and secondary based on disease aetiology, occurrence without any underlying cause is primary and disease presentation with known underlying reasons is termed as secondary [4]. However, a female predominance has been reported in India [5]. It is distinguished by a dense, concertina-like grayish-white fibrotic membrane that envelops the small intestine either entirely or partly. Acute intestinal obstruction is the most frequent manifestation of symptomatic abdominal cocoon [4,6]. Cases of abdominal cocoon syndrome reported in recent research literature have been listed in [Table/Fig-5] [2,6-19]. On the contrary, this case presented with obstipation and abdominal distension. The pathophysiology of this illness is subject to several hypotheses, with a previous history of abdominal tuberculosis being one of the common reasons in rural areas of India [20]. There was no history of abdominal tuberculosis noted in this patient. The differential diagnosis based on presenting features included encapsulating peritoneal sclerosis, small bowel obstruction, gross ascites, calcifying fibrous tumour of mesentery, omental rhabdomyosarcoma, and abdominal tuberculosis, which was ruled out intraoperatively as it was found to be a localised mass consisting of adhered bowel loops. Abdominal cocoon syndrome carries a high morbidity and mortality rate. The overall mortality rate of abdominal cocoon syndrome has been reported as 35%-74% based on the severity of the disease [21]. Surgical management is recommended due to the nature of adhesions and

## DISCUSSION

'Abdominal cocoon syndrome' is also known as 'Encapsulating peritoneal sclerosis'. 'Sclerosing encapsulated peritonitis' was first identified in 1907 by Owtschinnikow and was termed as

S. No.	Author	Year/ Place	Age (in years)/Sex	Presenting complaints	Previous significant history	Clinical features	Surgical management
1	Chorti A et al., [7]	2022, Greece	51/ M	Diffuse abdominal pain, loss of appetite, and constipation	No medical history	Sluggish bowel sounds, diffuse intraperitoneal fluid with dilated small bowel loops	Exploratory laparotomy
2	Karona P et al., [6]	2021, Greece	49/M	Recurrent obstructive ileus.	Recurrent obstructive ileus, counting two admissions within three months, hyperlipidaemia.	Recurrent obstructive ileus	Exploratory laparotomy
3	Palacio-Lopez F et al., [8]	2021, Mexico	29/F, 13 weeks pregnant	Abdominal pain, epigastrium and radiated to both hypochondria	Irritable bowel syndrome	Rigid abdomen, abdominal distension	Exploratory laparotomy with excision of entire sclerosing membrane entrapping the bowel loop
4	Mousavi MA et al., [9]	2022, Iran	43/M	Generalised abdominal pain, preferably hypogastric, recurrent nausea and vomiting with no appetite	Emergency surgery for acute appendicitis ten yrs, appendectomy	Dilated loops were explored between pancreases and stomach that are continued to the ileum, distended duodenum to the distal ileum and secum	Removal of the membrane performed by laparotomy
5	Saleem A et al., [10]	2023, Kuwait	32/ M	Left iliac fossa pain, associated with multiple vomiting episodes and alternating bowel habits (diarrhea and constipation)	No medical history	Distended abdomen, exaggerated bowel sounds	Fibrous band resection, and adhesiolysis
6	Alsadery HA et al., [2]	2022, Saudi Arabia	26/ M, 36/M (Indians)	Abdominal pain associated with nausea and vomiting	no medical history	Multiple dilated fluid-filled small bowel loops in the center of the abdominal cavity, non-enhancing capsules encasing the small bowel loops with mesenteric congestion	Complete surgical excision of the sac by exploratory laparotomy and adhesiolysis
7	Mohammed F et al., [11]	2021, Sudan	16/ F	Persistent vomiting, nausea, constipation, and epigastric abdominal pain along with weight loss.	History of on-and-off constipation	Distended abdomen with full flanks, and it was dull on percussion.	Laparotomy, adhesiolysis and appendectomy
8	Keese D et al., [12]	2021, Germany	12/ M	Distended abdomen, refusal of feeds, and episodes of abdominal pain	Xq24 deletion syndrome, Resection	8 week after primary surgery for resection of symptomatic jejunal angiodysplasia	Extensive adhesiolysis



9	Akbas A et al., [13]	2020, Turkey	30/ M	Nausea, vomiting, and abdominal pain	Several previous abdominal pain attacks	Tender and distended abdomen, dilatation and wall thickness in the terminal ileum	Laparotomy
			47/ M	Constipation, nausea, and vomiting for three days	No medical history	Abdominal distension, proximally dilated clustered terminal ileum and caecum	Laparotomy
			38/F	Swelling, vomiting, and constipation for a week	History of sigmoid colon tumor 2 months back with left hemicolectomy	Abdominal distension	Exploratory laparotomy
			64/F	Abdominal swelling, vomiting, and constipation × 3 days	Total abdominal hysterectomy with bilateral salpingo-oophorectomy, pelvic and para-aortic lymph node dissection due to endometrium cancer a month ago	Abdominal distension	Exploratory laparotomy, adhesiolysis
10	Tajaddini A et al., [14]	2023,	47/M	Abdominal distention, constant vomiting, constipation, Weight loss	Intermittent abdominal pain and constipation	A painless mass was palpated in the abdomen, mainly in the central part of the abdomen, with non-symmetrical distention and was dull on percussion	Exploratory laparotomy, resected and enteroenteric end-to-end small bowel jejunioleal anastomosis
11	Thambi VD et al., [15]	2023, Rwanda	30/M (Asian)	Right-sided upper abdominal pain accompanied by nausea, vomiting, and bloating, weight loss	Patient relied on semiliquid foods	Abdominal distension	Adhesiolysis, Appendectomy
12	Li F and Xie M et al., [16]	2023, China	56/M	Unbearable upper abdominal pain, vomiting	No medical history	Severe bowel obstruction	Exploratory laparotomy
13	Surriah MH, [17]	2023, Iraq	15/F	Abdominal pain, repeated vomiting, and absolute constipation with loss of weight × 3 days	No medical history	Complete intestinal obstruction	Exploratory midline laparotomy, inter-loop adhesions with appendicectomy
14	Omona K et al., [18]	2021, Uganda	27/F	Central abdominal pain, failure to pass stool and bilious vomiting × 3 days	No medical history	Several episodes of related obstructive symptoms that would be self-limiting for a year	Blunt dissection, Laparotomy.
15	Mehmood M et al., [19]	2023, Pakistan	59/M	Growing TP increasing stomach pain and frequent projectile vomiting, followed by absolute constipation × 1 day	Hypertension × 3 years	Abdominal distension	Exploratory laparotomy

**[Table/Fig-5]:** Review of literature of the included studies on abdominal cocoon syndrome [2,6-19].

bowel entrapment. A complete sclerosing membrane is removed for resolution of associated complications and recurrence with resection/anastomosis required only in cases of iatrogenic damage [22,23].

## CONCLUSION(S)

The preoperative diagnosis might be incidental in cases of abdominal cocoon syndrome, as clinical symptoms are unclear and delayed diagnosis is related to adverse outcomes, including mortality. Radiological methods can aid in preoperative confirmation of the diagnosis, thereby assisting in surgical management.

## REFERENCES

- Foo KT, Ng KC, Rauff A, Foong WC, Sinniah R. Unusual small intestinal obstruction in adolescent girls: The abdominal cocoon. *Br J Surg.* 1978;65(6):427-30.
- Alsadery HA, Busbait S, AlBlowi A, Alsawidan M, AlBisher HM, Alshammary S. Abdominal cocoon syndrome (idiopathic sclerosing encapsulating peritonitis): An extremely rare cause of small bowel obstruction-Two case reports and a review of literature. *Front Med (Lausanne).* 2022;9:1003775. Doi:10.3389/fmed.2022.1003775.
- Hu Q, Shi J, Sun Y. Abdominal cocoon with intestinal perforation: A case report. *Front Surg.* 2021;8:747151. Doi: 10.3389/fsurg.2021.747151.
- Aziz W, Malik Y, Haseeb S, Mirza RT, Aamer S. Abdominal cocoon syndrome: A laparoscopic approach. *Cureus.* 2021;13(7):e16787. Doi: 10.7759/cureus.16787.
- Akbulut S. Accurate definition and management of idiopathic sclerosing encapsulating peritonitis. *World J Gastroenterol.* 2015;21(2):675. Doi: 10.3748/wjg.v21.i2.675.
- Karona P, Blevrakis E, Kastanaki P, Tzouganakis A, Kastanakis M. Abdominal cocoon syndrome: An extremely rare cause of small bowel obstruction. *Cureus.* 2021;13(4):e14351. Doi: 10.7759/cureus.14351.
- Chorti A, Panidis S, Konstantinidis D, Cheva A, Papavramidis T, Michalopoulos A, et al. Abdominal cocoon syndrome: Rare cause of intestinal obstruction-Case report and systematic review of literature. *Medicine (Baltimore).* 2022;101(27):e29837. Doi: 10.1097/MD.00000000000029837.
- Palacio-Lopez F, Garcia-Blanco MD, Gonzalez-Hermosillo LM, Zuñiga-Montiel JA, Roldan-Valadez E. Abdominal cocoon syndrome in a 13-weeks pregnant woman. *Russian Electronic Journal of Radiology.* 2021;11(3):198-203. Doi: 10.21569/2222-7415-2021-11-3-198-203.
- Mousavi MA, Shaghaghi A, Sabouri M, Yousefian R. Abdominal cocoon syndrome as rare cause of intestinal obstruction: A case report. *Int J Surg Case Reps.* 2022;98:107547. Doi: 10.1016/j.ijscr.2022.107547.
- Saleem A, Alenezi A, Alenezi S, Hassan M, Alshammari K, Alkandari M. Abdominal cocoon syndrome; A rare etiology of intestinal obstruction; A case report. *Int J Surg Open.* 2023;54:100607. Doi: 10.1016/j.ijso.2023.100607.
- Mohammed F, Abdulkarim M, Yasir Al, Taleballah O, Shani D, Salih N. Abdominal cocoon syndrome, a case report of a rare disease entity causing intestinal obstruction. *Int J Surg Case Reps.* 2021;87:106401. Doi: 10.1016/j.ijscr.2021.106401.
- Keese D, Schmedding A, Saalabian K, Lakshin G, Fiegel H, Rolle U. Abdominal cocoon in children: A case report and review of literature. *World J Gastroenterol.* 2021;27(37):6332-44. Doi: 10.3748/wjg.v27.i37.6332.
- Akbas A, Hacim NA, Dagmura H, Meric S, Altinel Y, Solmaz A. Two different clinical approaches with mortality assessment of four cases: Complete and incomplete type of abdominal cocoon syndrome. *Case Reps Surg.* 2020;2020:4631710. Doi: 10.1155/2020/4631710.
- Tajaddini A, Fallahi M, Haghshenas H, Nourmohammadi SS, Ghahramani L, Shahriarirad R. Primary abdominal cocoon syndrome manifesting with Chilaiiditi syndrome and intestinal obstruction: A case report. *Clin Case Reps.* 2024;12(1):e8363. Doi: 10.1002/ccr3.8363.
- Thambi VD, Kowtha P, Fatima A, Devarala B, Mushtaq J, Shariff S, et al. Abdominal cocoon syndrome, a rare cause of intestinal obstruction presenting in an Asian adult male: A case report. *Ann Med Surg (Lond).* 2023;85(4):986-89. Doi: 10.1097/MS9.000000000000288.
- Li F, Xie M. Abdominal cocoon syndrome (ACS): A case report of a Chinese male diagnosed idiopathic ACS with inborn short intestine. *Ann Med Surg.* 2024;86(2):1152-55. Doi: 10.1097/MS9.0000000000001639.
- Surriah MH. Abdominal cocoon syndrome (ACS) or idiopathic sclerosing peritonitis: An extremely rare cause of intestinal obstruction. *Arab Board Med J.* 2023;24(1):42-47. Doi: 10.4103/abmj.abmj\_26\_22.
- Omona K, Ssewanyana Y, Ssekitooleko B, Ongaro D. A case of abdominal cocoon syndrome: A rare cause of small bowel obstruction at Aber hospital in northern uganda. *Int J Med.* 2021;9(1):48-53.

- [19] Mahmood M, Mirza AA, Sree GS, Vakkalagadda NP, Mumtaz H. Abdominal cocoon syndrome. A rare cause of mechanical intestinal obstruction: A case report. *Int J Surg Case Reps.* 2023;103:107875. Doi: 10.1016/j.ijscr.2023.107875.
- [20] Singhal M, Krishna S, Lal A, Narayanasamy S, Bal A, Yadav TD, et al. Encapsulating peritoneal sclerosis: The abdominal cocoon. *Radiographics.* 2019;39(1):62-77. Doi: 10.1148/rg.2019180108.
- [21] Moriles KE, Hashmi MF. Encapsulating Peritoneal Sclerosis. [Updated 2023 Feb 19]. In: StatPearls [Internet]. Treasure Island (FL): StatPearls Publishing; 2024. Available from: <https://www.ncbi.nlm.nih.gov/books/NBK574525/>.
- [22] Saqib SU, Farooq R, Saleem O, Moeen S, Chawla TU. Acute presentation of cocoon abdomen as septic peritonitis mimicking with strangulated internal herniation: A case report. *Surg Case Rep.* 2021;7(1):93. Doi: 10.1186/s40792-021-01179-7.
- [23] Li N, Zhu W, Li Y, Gong J, Gu L, Li M, et al. Surgical treatment and perioperative management of idiopathic abdominal cocoon: A single-center review of 65 cases. *World J Surg.* 2014;38(7):1860-67. Doi: 10.1007/s00268-014-2458-6.

**PARTICULARS OF CONTRIBUTORS:**

1. Junior Resident, Department of General Surgery, Jawaharlal Nehru Medical College and Datta Meghe Institute of Higher Education and Research, Sawangi (Meghe), Wardha, Maharashtra, India.
2. Professor, Department of General Surgery, Jawaharlal Nehru Medical College and Datta Meghe Institute of Higher Education and Research, Sawangi (Meghe), Wardha, Maharashtra, India.
3. Assistant Professor, Department of General Surgery, Jawaharlal Nehru Medical College and Datta Meghe Institute of Higher Education and Research, Sawangi (Meghe), Wardha, Maharashtra, India.
4. Junior Resident, Department of General Surgery, Jawaharlal Nehru Medical College and Datta Meghe Institute of Higher Education and Research, Sawangi (Meghe), Wardha, Maharashtra, India.

**NAME, ADDRESS, E-MAIL ID OF THE CORRESPONDING AUTHOR:**

Dr. Abhilasha Bhargava,  
Junior Resident, Department of General Surgery, Jawaharlal Nehru Medical College and Datta Meghe Institute of Higher Education and Research, Sawangi (Meghe), Wardha-442001, Maharashtra, India.  
E-mail: abhilasha0318@gmail.com

**PLAGIARISM CHECKING METHODS:** [Jain H et al.]

- Plagiarism X-checker: Jan 02, 2024
- Manual Googling: Feb 03, 2024
- iThenticate Software: Mar 15, 2024 (6%)

**ETYMOLOGY:** Author Origin**EMENDATIONS:** 8**AUTHOR DECLARATION:**

- Financial or Other Competing Interests: None
- Was informed consent obtained from the subjects involved in the study? No
- For any images presented appropriate consent has been obtained from the subjects. Yes

Date of Submission: **Jan 01, 2024**Date of Peer Review: **Jan 31, 2024**Date of Acceptance: **Mar 18, 2024**Date of Publishing: **May 01, 2024**